

# A comparison of endoscopic and microscopic removal of wax: a randomised clinical trial

Pothier, D.D., Hall, C., & Gillett, S.

Departments of Otolaryngology, Royal United Hospital, Bath, UK

Accepted 14 July 2006

*Clin. Otolaryngol.* 2006, **31**, 375–380

**Objectives:** Using a microscope to achieve a view of the canal during dewaxing is the most commonly performed method of dewaxing in secondary care, but an endoscope can also be used. We set out to compare endoscopic and microscopic dewaxing.

**Design:** Randomised clinical trial.

**Setting:** Otolaryngology Outpatient Department.

**Participants:** One hundred participants selected sequentially from patients requiring dewaxing of their ears to allow examination of the tympanic membrane. Patients with external or middle ear pathology were excluded.

**Methods:** Patients were randomly assigned to have dewaxing performed using microinstruments aided by vision with a microscope or an endoscope. All participants who were entered the study completed the study.

**Main outcome measures:** Levels of pain and discomfort experienced by the participants were assessed by a visual analogue scale (VAS). Difficulty of performing the dewax-

ing indicated by the endoscopist using a VAS. The length of time taken to perform the dewaxing was also recorded.

**Results:** Endoscopic dewaxing was less uncomfortable than microscopic dewaxing for patients (VAS median values 5 and 25 respectively;  $P < 0.002$ ) as well as less painful (VAS median values 3.5 and 10 respectively;  $P < 0.075$ ). Endoscopic dewaxing was easier to perform than microscopic dewaxing (VAS median values for difficulty were 9 and 20 respectively;  $P < 0.005$ ) and took less time (mean time for endoscopic dewaxing was 1.8 min versus 3.3 min for microscopic dewaxing ( $P < 0.001$ )). Ninety-one per cent of ears could be dewaxed with a Jobson–Horne probe or wax hook.

**Conclusions:** The cost of an operating microscope suitable for use with dewaxing is approximately 10 times that of a suitable endoscope, dewaxing is a cheaper alternative to microscopic dewaxing that has benefits for the patient and clinician.

Removal of wax from the ear canal is a procedure undertaken by most ENT surgeons on a regular basis; this may be to allow a full view of the tympanic membrane or to relieve symptoms of impacted wax. Although some clinicians will use a head mirror and speculum to remove wax under direct vision, it is common practice to use a suction to dewax ears under microscopic vision. In primary care, syringing is the most commonly used technique of dewaxing with 2.3-million people requiring management of impacted wax annually in the UK, with syringing being performed approximately 4 million times annually.<sup>1</sup> Much of this routine dewaxing is performed by practice nurses.<sup>2</sup>

General Practitioners (GPs) are becoming reluctant to offer syringing as it is associated with clinically significant complications. As there is no access to the specialised equipment required for dewaxing under a microscope in

primary care, syringing remains the only option available to most GPs and practice nurses.

Endoscopic dewaxing, first described by one of the authors,<sup>3</sup> involves the use of an endoscope to view the ear canal whilst wax is removed mechanically using a Jobson–Horne probe. This may provide a cheaper alternative that, with sufficient training in its use, offers a reliable method of removing wax with a clear view of the ear canal and its contents.

We set out to compare endoscopic dewaxing to removal of wax under a microscope, the current gold standard of wax removal.

## Null hypotheses

The choice of microscope or endoscope to provide a view of the external auditory meatus during dewaxing of a patient's ear has no effect on the following:

1 Levels of pain or discomfort that are experienced by the patient.

Correspondence: D.D. Pothier, Department of Otolaryngology, Royal United Hospital, Bath, UK, Tel.: 01225 824550; fax: 0797 4012299; e-mail: email@davepothier.com.

© 2006 The Authors

Journal compilation © 2006 Blackwell Publishing Limited, *Clinical Otolaryngology*, **31**, 375–380

- 2 Ease of dewaxing.
- 3 Time taken to perform dewaxing.

## Methods

A prospective non-blinded randomised clinical trial was designed.

### Participants

One hundred consecutive patients, with a history of impacted ear wax, were recruited between 1 March 2006 and 3 May 2006. They were all attendees at the Otolaryngology outpatient clinic at the Royal United Hospital, Bath.

Criteria for inclusion were patients requiring removal of wax from the ear canal to allow a full view of the tympanic membrane. All patients with active or previous external or middle ear pathology were excluded; this included patients with mastoid cavities, active ear infections or any known abnormality of the tympanic membrane (perforation or retraction).

Patients were assigned into one of two groups: one group underwent dewaxing using an endoscope, the other group underwent dewaxing using a microscope.

### Randomisation

Randomisation was by means of opaque envelopes, each containing a single proforma, on which the specified group was marked (50 envelopes in each group); the envelope was blindly selected at random by the patient. The endoscopist carrying out the procedure opened the envelope in view of the patient, who was then informed of the allocation.

### Technique

Dewaxing using the endoscope was performed with a Karl Storz 4 mm 0° oto-endoscope (Karl Storz, Slough, Berkshire, UK) and a portable light emitting diode lightsource (GVR Products, Stoke-on-Trent, UK). The technique involves using the endoscope to retract the tragus and view the ear canal to allow removal of wax under vision. Dewaxing using a microscope was performed using a Zeiss OPMI microscope (Carl Zeiss Ltd, Welwyn Garden City, UK) with a Toynbee aural speculum.

To reduce bias associated with learning a new technique, only clinicians who had dewaxed at least 50 ears using each technique were invited to participate in the study. With both techniques, removal of wax was attempted with a Jobson–Horne probe in the first instance; if

this was unsuccessful, a wax hook or crocodile forceps were used. If dewaxing was still not successful, suction with a Zoellner sucker was attempted. Where either technique was unsuccessful, the alternate technique was attempted.

### Outcome measurements

A group of 10 patients who had just undergone dewaxing of their ears under a microscope were asked how they thought that the experience of the process could be described. Most reported clearly that there were two distinct sensations; pain and discomfort. We noticed that sensations of discomfort were associated with an uncomplicated but protracted dewaxing, but pain was felt when the tympanic membrane or the skin of the ear canal was stimulated.

To record these sensations in our trial participants, the patient was asked to complete a visual analogue score sheet after the dewaxing had been performed. The patient was asked to indicate on a visual analogue scale (VAS) the pain caused by the procedure (0, no pain; 100, very painful) and the discomfort caused by the procedure (0, no discomfort; 100, very uncomfortable). Patients had the difference between the two scales explained to them and a clinician was always available to answer any questions arising from the questionnaire.

The clinician performing the dewaxing was asked to indicate on a VAS the difficulty of performing the dewaxing, record the percentage of the tympanic membrane obscured by wax prior to randomisation and the time taken to complete the dewaxing.

The VAS were each 100 mm in length. The measurement of the visual analogue score was to the nearest millimetre with zero being taken as the left edge of the scale.

### Sample size calculation

A sample size calculation determined that 50 participants in each group would provide a power of 90% to detect a difference in mean values of 10 points assuming a standard deviation of 15, using a two-group *t*-test, at 5% significance.

### Statistical analysis

Data were imported into a statistical software package SPSS 11.0 (SPSS Inc., Chicago, IL, USA) for analysis. Distribution of data from the visual analogue scores for discomfort, pain, difficulty of dewaxing were analysed for normality. The data for discomfort, pain and difficulty were not normally distributed and a Mann–Whitney

*U*-test was used to determine levels of statistical significance for these variables. Data for time taken were normally distributed and an unpaired *t*-test was used to compare mean values. An intention-to-treat analysis was followed.

#### Ethical considerations

The study had received the necessary review and approval from the local research ethics committee prior to recruitment.

Participation in the study was on a voluntary basis for patients who would need removal of wax from their ear(s) as a part of their consultation. The patients were provided with a pre-prepared patient information leaflet and written consent was obtained.

#### Results

All patients who gave consent to participate in the study completed the dewaxing and the questionnaire; no patient withdrew consent at any time. The mean age of participants was 57.8 years (range 16–91, SD 17.0); 61% of participants were male and 39% were female (see Table 1 for demographics of each group). No complications were reported at the time of dewaxing in either group.

Of the 50 patients in the endoscopic group, 5 (10%) required conversion to microscopic dewaxing. Of these, three were successfully dewaxed; the two remaining patients were sent home to use cerumenolytics before reattending to finish the dewaxing. Of the 50 patients in the microscopic group, two had to be converted to endoscopic dewaxing; one was successfully dewaxed; the other was sent home for cerumenolytics (Figure 1). Two patients sustained minor bleeding from their ear canals; one in each group. No other complications were reported. The use of a Jobson–Horne probe or wax hook/microforceps was successful in 91% of ears. Of the remaining nine of ears (9%), suction was attempted; this was successful in six of the ears, the remaining three required the prescription of cerumenolytics and a further appointment to remove residual wax.

#### Levels of pain and discomfort

Figure 2 shows the distribution of visual analogue scores for discomfort experienced by the patient. Endoscopic dewaxing was significantly less uncomfortable than microscopic dewaxing (median values = 5 and 25 respectively;  $P = 0.002$ ). Figure 3 shows the distribution of visual analogue scores for pain experienced by the patient. Endoscopic dewaxing was less painful than microscopic dewaxing, but this was not statistically significant (median values = 3.5 and 10 respectively;  $P = 0.075$ ).

#### Difficulty of dewaxing

Figure 4 shows the distribution of visual analogue scores for difficulty of dewaxing. Dewaxing was significantly easier using the endoscopic technique than the microscopic technique (median values = 9 and 20 respectively;  $P = 0.005$ ).

In the endoscopy group, 20 patients had their tympanic membrane completely obscured by wax (40%), as did 26 patients in the microscopy group (52%). The mean amount of wax obscuring the tympanic membranes of the groups was not significantly different ( $P = 0.69$ ).

Time taken to perform dewaxing using the endoscope was significantly less than that required to perform microscopic dewaxing, with a mean of 1.8 min compared with a mean of 3.3 min for microscopic dewaxing ( $P = 0.001$ ).

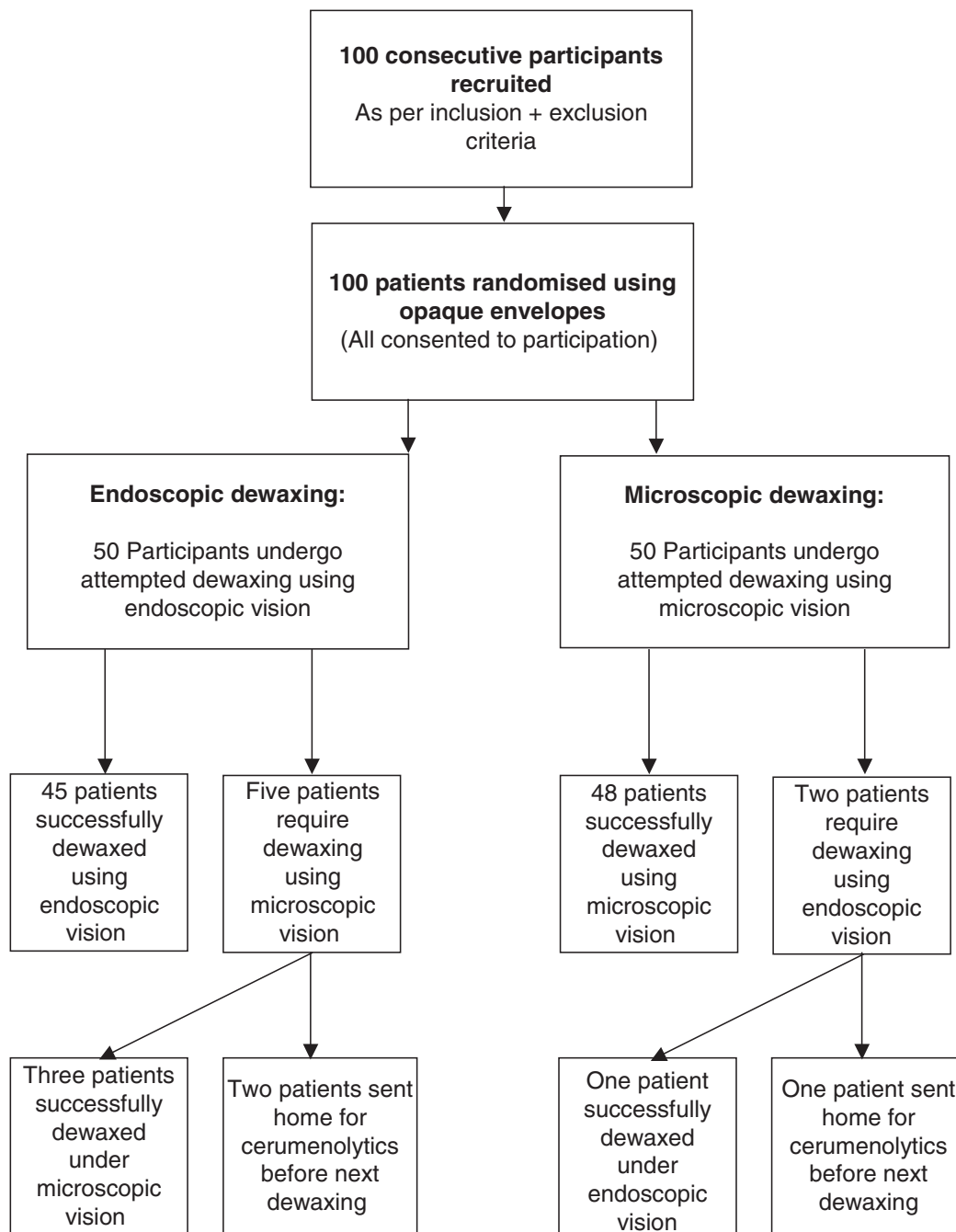
#### Discussion

Syringing is effective in improving the symptoms of impacted wax, including the sensation of blockage and hearing loss,<sup>4</sup> but is associated with some serious complications,<sup>5,6</sup> the commonest being otitis externa and perforation of the tympanic membrane.<sup>7</sup> It is estimated that 1 : 1000 episodes of ear syringing results in a significant complication.<sup>8</sup> Blake *et al.*<sup>7</sup> demonstrated significant levels of litigation associated with these complications.

Endoscopic dewaxing represents a relatively low-cost option of performing dewaxing under vision. An endoscope

**Table 1.** Demographics of each group

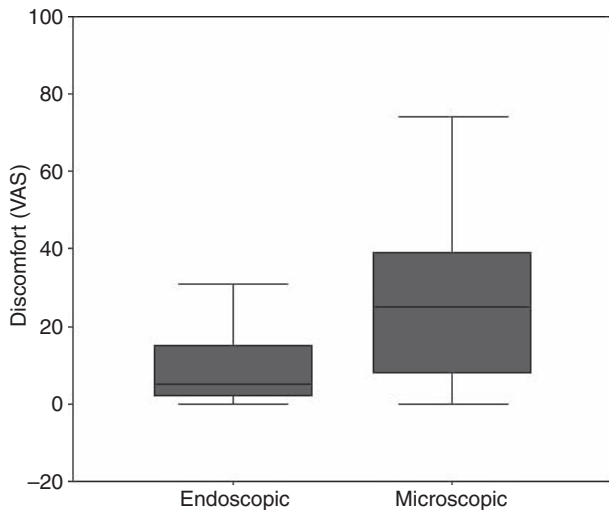
	Mean age (years)	Range (years)	SD (years)	Male (%)	Female (%)	Mean % wax obscuring tympanic membrane
Microscopic	58.3	18–91	17.3	62	38	65.5
Endoscopic	57.2	16–87	16.86	60	40	72.0



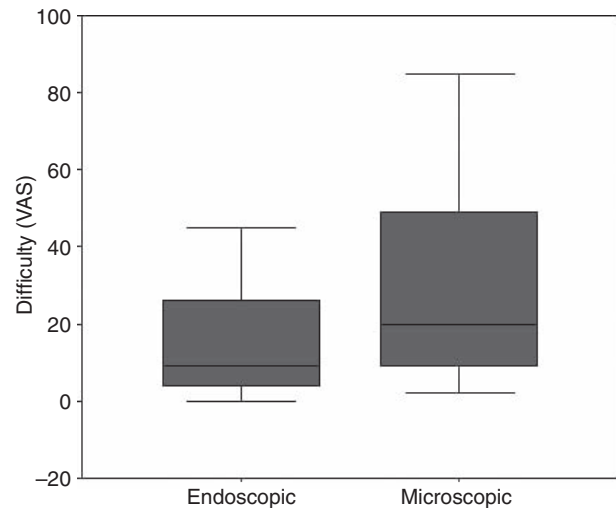
**Fig. 1.** Flowchart of participants through study.

and portable light source is significantly cheaper than a microscope<sup>3</sup> which makes the widespread use of this technique an attractive option for those offering dewaxing in primary care. This is supported by the fact that the use of suction was only required in 9% of the ears. The use of endoscopic dewaxing in primary care is likely to reduce the number of patients who will need to undergo syringing to dewax their ears as well as reduce the number of patients who are referred to secondary

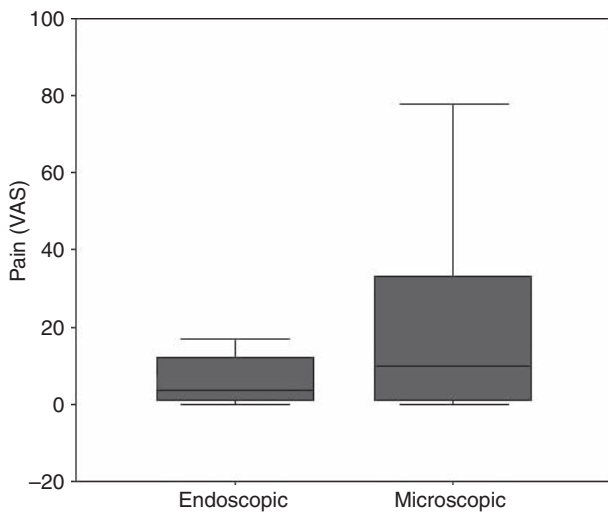
care to have their wax removed. Where it is introduced into secondary care, the need for a microscope is reduced which may allow a more comprehensive service to be delivered by specialists where resources and equipment are limited. Endoscopic dewaxing is likely also reduce time spend dewaxing ears as well as achieving a better view of the tympanic membrane. The addition of a camera to the endoscope allows this technique to be taught easily.



**Fig. 2.** Box plot of visual analogue to scores (0–100) for discomfort for the groups dewaxed using an endoscope and a microscope (medians = 5 and 25 respectively). Dewaxing with an endoscope was significantly less uncomfortable than with a microscope ( $P = 0.002$ ).



**Fig. 4.** Box plot of visual analogue to scores (0–100) for difficulty of dewaxing for the groups dewaxed using an endoscope and a microscope (medians = 9 and 20 respectively). Dewaxing with an endoscope was significantly easier than with a microscope ( $P = 0.005$ ).



**Fig. 3.** Box plot of visual analogue to scores (0–100) for pain for the groups dewaxed using an endoscope and a microscope (medians = 3.5 and 10 respectively). There was a tendency for dewaxing with an endoscope to be less painful than with a microscope, but this was not statistically significant ( $P = 0.075$ ).

The cost of an oto-endoscope is approximately ten times less than an operating microscope (£800 versus £8000). This is still a significant outlay for a primary care practice, but the introduction of endoscopic dewaxing will substantially reduce the need for syringing and referral to secondary care.

#### Limitations of the study

The VAS used in this study have been used before in a previous studies assessing pain and discomfort associated with the use of lubrication in nasendoscopy,<sup>9</sup> but have not been formally validated.

In this study, neither the participant nor the clinician were blinded to the type of dewaxing performed; this may have introduced bias into the results of the levels of discomfort and pain experienced by the participant as well as the score for ease of dewaxing experienced by the clinician.

Patients with ear pathology were excluded from the study as this is a new described technique; the authors wanted to assess its effectiveness where routine dewaxing is required as well as its potential for introduction to primary care. Further research is required to assess the usefulness of this technique in otitis externa and the cleaning of mastoid cavities.

#### Technique of endoscopic dewaxing

There is a substantial learning curve involved in endoscopic dewaxing, during which the advantages of the technique may not be immediately apparent.

Once the technique is mastered, however, the technique offers a much wider field of view during dewaxing and a far greater degree of operational freedom with instruments than a microscope and speculum. The angle at which the Jobson–Horne probe can be inserted into

the ear allows gentle teasing of the wax from the ear canal rather than requiring it to be pulled from the canal skin or sucked out with a sucker.

### Conclusions

Endoscopic dewaxing, is a potentially safe and arguably more effective alternative to syringing. This method would allow the removal of wax from ears with perforated tympanic membranes and even mastoid cavities in primary care or where a microscope is not available. There is evidence that endoscopic wax removal is more comfortable and less painful than microscopic dewaxing and is easier to perform once a level of proficiency has been attained. Training in the technique is recommended before endoscopic dewaxing is attempted by non-otolaryngologists.

### Conflict of interest

None declared.

### Acknowledgements

The authors would like to thank Karl Storz for the loan of the oto-endoscopes and GVR products for the loan of the portable light sources used in this study.

### References

- 1 Guest J.F., Greener M.J., Robinson A.C. *et al.* (2004) Impacted cerumen: composition, production, epidemiology and management. *QJM* **97**, 477–488
- 2 Sharp J.F., Wilson J.A., Ross L. *et al.* (1990) Ear wax removal: a survey of current practice. *BMJ* **301**, 1251–1253
- 3 Pothier D.D. (2006) How we do it: technical note: endoscopic removal of cerumen. *Clin. Otolaryngol.* **31**, 153–155
- 4 Memel D., Langley C., Watkins C. *et al.* (2002) Effectiveness of ear syringing in general practice: a randomised controlled trial and patients' experiences. *Br. J. Gen. Pract.* **52**, 906–911
- 5 Bapat U., Nia J. & Bance M. (2001) Severe audiovestibular loss following ear syringing for wax removal. *J. Laryngol. Otol.* **115**, 410–411
- 6 Prasad K.S. (1984) Cardiac depression on syringing the ear. A case report. *J. Laryngol. Otol.* **98**, 1013
- 7 Blake P., Matthews R. & Hornibrook J. (1998) When not to syringe an ear. *N. Z. Med. J.* **111**, 422–424
- 8 Bird S. (2003) The potential pitfalls of ear syringing. Minimising the risks. *Aust. Fam. Physician* **32**, 150–151
- 9 Pothier D.D., Awad Z., Whitehouse M. *et al.* (2005) The use of lubrication in flexible fiberoptic nasendoscopy: a randomized controlled trial. *Clin. Otolaryngol.* **30**, 353–356

Copyright of *Clinical Otolaryngology* is the property of Blackwell Publishing Limited and its content may not be copied or emailed to multiple sites or posted to a listserv without the copyright holder's express written permission. However, users may print, download, or email articles for individual use.